



Case report

Surgical technique for approaching chronic or persistent macular holes: Two case reports

Marcelo Zas^{a,*}, Andres F. Lasave^b, Alejandro Alfano^a, Mario Saravia^c^a From the Ophthalmology Department, Retina Section, Hospital de Clínicas "José de San Martín", School of Medicine, University of Buenos Aires, Argentina^b Retina and Vitreous Service, Clínica Privada de Ojos, Mar del Plata, Buenos Aires, Argentina^c Retina and Vitreous Department, Department of Ophthalmology, Hospital Universitario Austral, Buenos Aires, Argentina

ARTICLE INFO

Keywords:

Chronic macular hole
 Macular retinal detachment
 Persistent macular hole
 Retinotomy

ABSTRACT

Purpose: To report the anatomic and functional outcomes of an innovative surgical technique for either chronic or persistent macular holes (MHs).

Observations: A consecutive retrospective interventional case series of 2 patients with chronic macular hole in one case and persistent macular hole in the other case were included. Surgical technique involves pars plana vitrectomy, use of triamcinolone acetate for posterior hyaloid staining followed by internal limiting membrane peeling in case number 1, macula area is detached by means of subretinal injection of balanced salt solution (BSS) through 3 puncture retinotomies strategically placed. Fluid–air exchange is done and gas tamponade is injected. Face-down position is required. Preoperative, and postoperative best corrected visual acuity was recorded. Spectral-domain optical coherence tomography (SD-OCT) scans were registered and compared. Case number 1 did not achieve a complete closure of the macular hole during a 6-month follow-up period. Case number 2 had successful hole closure after the procedure and was maintained for 12 months of follow up. No worsening in visual acuity was reported in neither eye, and improvement in visual acuity in case number 2 was observed from CF to 20/100 at the end of 12 months of follow up.

Conclusions and Importance: This surgical technique has previously demonstrated to provide resolution of chronic, large and persistent MH. However, in our case series we observed a complete closure of the macular hole in only one of two patients. Therefore, in spite of being a very small case series these results suggest the need to perform further studies to identify the presence of risk factors which could decrease the probability of failure with this interesting surgical technique.

1. Introduction

Pars plana vitrectomy (PPV) has been the gold standard for the treatment of idiopathic macular holes (MHs) for the past decades. More recently, the introduction of internal limiting membrane (ILM) peeling increased closure rates from 58% to 90%.^{1,2} However, macular hole closure rates depended strongly on base diameter, inner opening size, and chronicity.^{3,4} Therefore, surgical treatment is less likely to be successful in MHs larger than 400 μm and holes that have persisted for longer than 1 year.⁴ Several techniques were described to enhance surgical success in these cases including internal limiting membrane peeling, temporal arcuate retinotomy,⁵ compression of the retinal edges,⁶ autologous platelets,⁷ lens-capsule flap transplantation,⁸ heavy silicone tamponade,⁹ and inverted flap technique.¹⁰ However, there is no definitive method and no data to suggest a best method.

The aim of this report is to evaluate the anatomical and functional outcomes of two cases of chronic and persistent MHs using a surgical technique for closure enhancement, previously described by Oliver et al.¹¹

2. Findings

2.1. Surgical technique

Retina expansion technique for macular hole apposition (RETMA) has been previously described.^{11,12} It is performed as follows; A combined phaco-vitrectomy surgery is performed if needed (see Video, which demonstrates the procedure). After phacoemulsification surgery, a standard three-port pars plana vitrectomy approach is used with 23-gauge instrumentation. If required, extraction of the remainder

* Corresponding author. Araoz Street, PO BOX: 2755, 1st Floor, 1425DGQ, Ciudad Autónoma de Buenos Aires, Argentina.

E-mail address: consultoriordzas@gmail.com (M. Zas).

<https://doi.org/10.1016/j.ajoc.2020.100692>

Received 7 May 2018; Received in revised form 22 January 2019; Accepted 2 April 2020

Available online 09 April 2020

2451-9936/ © 2020 The Authors. Published by Elsevier Inc. This is an open access article under the CC BY-NC-ND license

(<http://creativecommons.org/licenses/by-nc-nd/4.0/>).

posterior hyaloid stained with triamcinolone acetonide (TA) is performed through a wide field lens. The internal limiting membrane is stained with Brilliant Blue dye and FINESSE™ Flex Loop (Grieshaber®/Alcon) is used to obtain the flap and either perform the peeling of the remnants ILM in the case of persistent MH or perform the complete peeling in the chronic hole case without previous vitrectomy. This surgery step is performed under a high-magnification macular lens (Hassan-Tornambe). After complete MLI peeling, three puncture retinotomies (one superior, one temporal and one inferior) are performed with a PolyTip® (MedOne) 23g/38g (0.12 mm) × 5 mm tip -gauge rigid retinal hydrodissection cannula. Subretinal infusion of balanced salt solution (BSS) is performed until each bleb connected with the macular hole, at which point it would stop enlarging. The infusion pressure is manually controlled with a syringe in the surgeon's right hand. An air-fluid exchange is performed but the subretinal fluid is not drained. SF6 at 20% concentration is injected into the posterior cavity. All ports were checked and sutured, if necessary. Face-down position was required during at least 6 hours per day for 3 days.

2.2. Case 1

A 61-year-old female was referred to our Department after reporting several months of decreased visual acuity in her right eye (OD) secondary to chronic macular hole. A large macular hole had been diagnosed by SD-OCT 20 months ago. Additionally, she had history of rhegmatogenous retinal detachment (RRD) surgery in the same eye 24 months ago. At presentation, her best corrected visual acuity (BCVA) was counting fingers (CF) OD and 20/30 left eye (OS). The anterior segment exam was within normal ranges in both eyes (OU). Intraocular pressure (IOP) measurement was 16 mmHg in both eyes. Dilated fundus examination in affected eye revealed a well-defined round foveal area representing a large macular hole (Fig. 1a). Retina was completely re-attached and a scar pigmentation secondary to endolaser was observed around the old retinal lesions. SD-OCT (Spectralis-OCT, Heidelberg Engineering, Heidelberg, Germany) confirmed a full-thickness macular hole with a relatively large base diameter (1430 µm) and elevated edges of the lesion (Fig. 1b) with a hole height of 404 µm. The macular hole index¹³ was < 0.50 (0.28). Additionally, a small accumulation of intraretinal fluid in the perilesional area was also observed. Due to the hole size and chronicity along with her history of retinal detachment, we decided to discuss extensively with the patient about different surgical options. After that, the patient decided to proceed with this surgical approach. (See Video Case 1, Supplemental Digital Content 1, which demonstrates the procedure). Thirty days after surgery her BCVA improved from CF to 20/200 and SD-OCT scans still showed an open but smaller macular hole (Fig. 1b). However, in spite of an initial anatomical restoration, the macular hole had not been closed after 3 months of follow-up. After 6 months post-operative follow-up, macular hole was observed bigger than in the previous visit and, for that reason we concluded that this novel surgical technique had failed to close the chronic macular hole in this patient (Fig. 1c).

2.3. Case 2

57-year-old female with history of idiopathic macular hole in her OS treated with pars plana vitrectomy with ILM peeling, and gas tamponade 12 months ago. However, persistent macular hole was identified immediately after surgery by means of slit lamp exam and SD-OCT scans, and then no changes were observed during 10 months of follow-up. At that time, BCVA was 20/20 in her OD and 20/400 in her OS.

A second surgery with more aggressive management than standard MH surgery was analyzed with the patient. She was aware that probability of success would be lower after each failed intervention. After reviewing the risks and benefits of several available techniques, it has been decided to perform the surgical technique for persistent macular hole described in this report. See Video Case 2, Supplemental Digital

Content 2, which demonstrates the procedure). The surgery was done without complications. One month after surgery a complete MH closure was observed with SD-OCT. BCVA improved from 20/400 to 20/200 and this visual recovery remains after 12 months of follow up (Fig. 2).

3. Discussion

This case series reports an idiopathic macular hole case which could not be closed by the standard approach, but it was successfully treated after second surgery by allowing for retinal mobilization with the Oliver's technique (Case number 2). However, we also describe another case (Case number 1) with history of large and chronic macular hole secondary to rhegmatogenous retinal detachment (RRD) surgery in which the same procedure was not able to close the hole. Both cases were performed by two experienced retinal surgeons. First case was done by first author (MZ) and the second case by a co-author (MS) of this case series.

Treatment of either persistent or chronic macular hole remains a significant challenge for vitreoretinal surgeons. Indeed, a few years ago, most of these cases were previously believed to be inoperable and left without treatment. The closure rate and visual outcome of full-thickness macular holes depend on size and chronicity. Therefore, large and chronic macular holes are known to have an unfavorable outcome.¹⁴ Surgical success in both chronic and persistent cases is low, achieving anatomical closure rate from 46.7% to 68.9%.¹⁴ When the MH persists after surgery, the underlying cause may be related to a residual vitreomacular traction, insufficient tamponade, or noncompliance to face down position. Additionally, it has been suggested an additional force that impedes edges approximation, even after relief of traction caused by the vitreous and the ILM.¹¹ In our cases the implemented technique uses the inherent elastic properties of the retina to bring the edges of the large macular hole closer, to promote closure.¹¹ Wong et al.¹⁵ reported a small sample of three patients with large macular holes which were closed following this retinal expansion technique achieving a 100% success rate. On the other hand, Gurelik et al.¹⁶ reported data for 10 eyes of 10 patients with history of large and persistent MHs treated with this surgical intervention. They describe similar outcomes reported by Wong, demonstrating a MHs closure in all patients during 6 months of follow-up. Recently Wong et al.¹² published the results of a case series of 16 patients with macular holes greater than 650 µm in "aperture" diameter treated with this surgical technique. Eighty-three percent (14 of 16) of eyes had successful hole closure after the procedure. At 12-month follow-up, no worsening in visual acuity was reported, and improvement in visual acuity was noted in 14 of 16 eyes.¹² In our report, we only obtained the macular hole complete closure in one of the two cases.

This surgical technique may be more aggressive than others previously described procedures for treating chronic macular holes. After subretinal BSS is injected and, a retinal detachment is generated especially close to the fovea, this procedure may cause an irreversible and functional damage of the photoreceptor after to be separated from the retinal pigment epithelium (RPE). However, Guerin et al.¹⁷ showed photoreceptor outer segment preservation and regeneration following experimental retinal detachment in rhesus monkeys. On the other hand, this technique may be related to the probability of causing functional defects of the visual field after causing macular detachment. Therefore, further studies are needed to evaluate pre-and post-operative functional sensitivity of the macular area with multifocal electroretinogram (ERG) to detect and quantify central cone function which could provide an answer to the questions concerning this surgical procedure.

Further long-term analysis and larger samples are necessary to understand the anatomic and functional potential after closure of these large macula holes. In addition, future randomized trials may be helpful in determining the best method in treating these chronic and persistent holes.

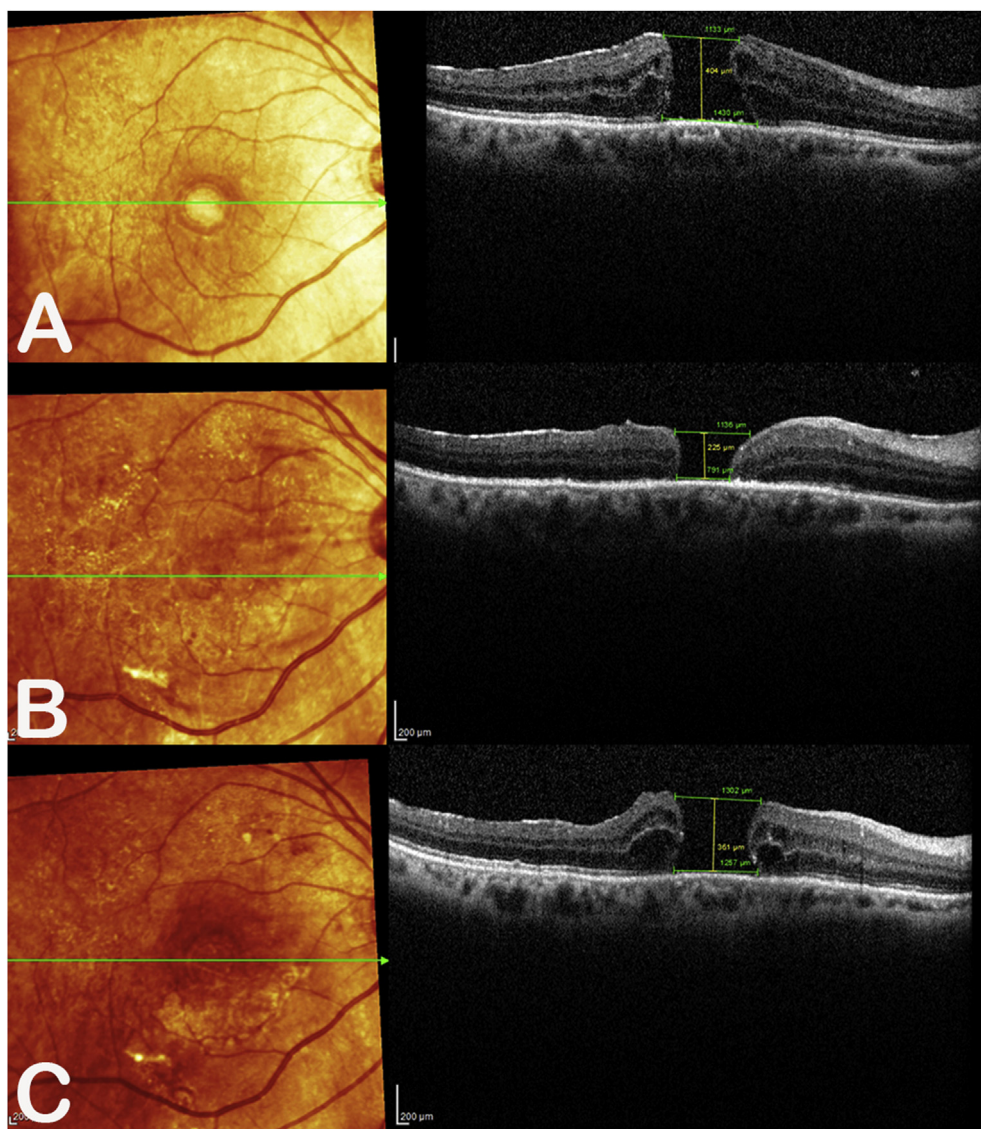


Fig. 1. Case 1. Preoperative spectral-domain optical coherence tomography (SD-OCT) the right eye. Preoperative macular hole index (ratio of the macular hole height to the base diameter) was < 0.28 (a). Three-month postoperative SD-OCT shows persistent of full thickness macular hole, although its size is decreased (b). After 6 months of follow-up, the macular hole not only is open but also is larger than first 3 months of follow-up (c).

4. Conclusion

We report a persistent macular hole case successfully treated with retina expansion technique for macular hole apposition. However, in other case with large and chronic macular hole, the same procedure was not able to close the hole. Future randomized trials may be helpful in determining the best method in treating these large holes. In addition, these results suggest the need to perform further studies to identified the presence of risk factors which could decrease the probability of failure with this interesting surgical technique.

Patient consent

Informed consent was obtained in writing from the patients before enrollment in this case report series and for publishing the results.

Funding

No funding or grant support.
The authors have no financial or proprietary interest in any of the products or techniques mentioned in this article.

Author contribution

All authors contributed equally to the manuscript.

Authorship

All authors attest that they meet the current ICMJE criteria for Authorship.

Declaration of competing interest

The following authors have no financial disclosures: MZ, AFL, AA,MS.

Acknowledgements

None.

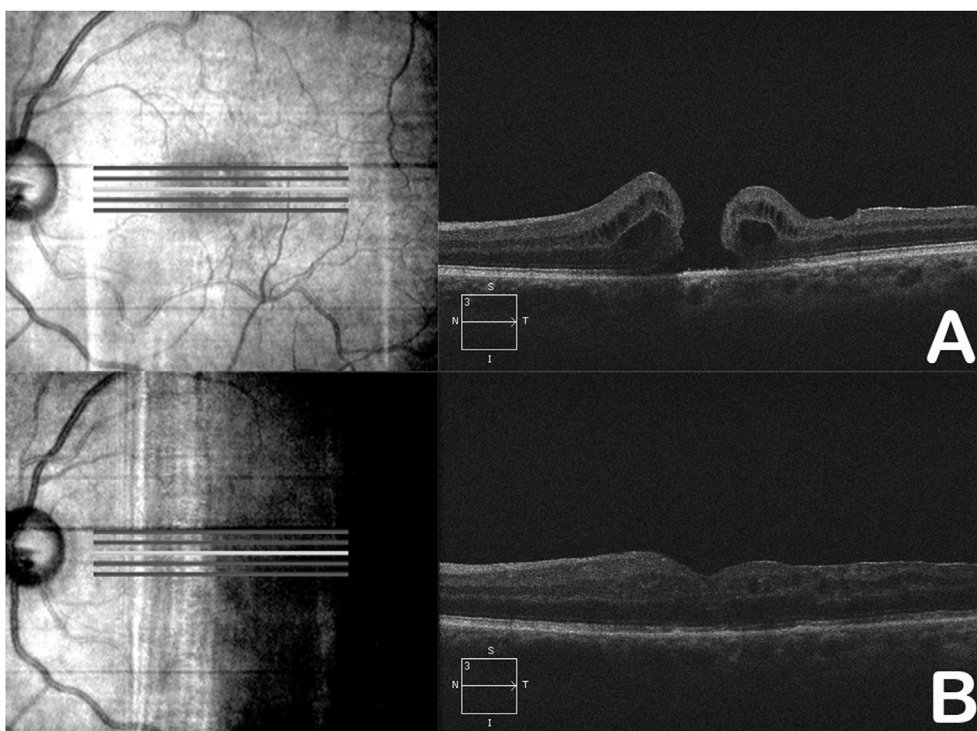


Fig. 2. Case 2. Preoperative SD-OCT of the right eye (a). Twenty-four-month postoperative SD-OCT demonstrates that the hole remains closed. Note the complete restoration of foveal architecture. Visual acuity was 20/200 at this follow-up visit (b).

Appendix A. Supplementary data

Supplementary data to this article can be found online at <https://doi.org/10.1016/j.ajoc.2020.100692>.

References

- Spiteri Cornish K, Lois N, Scott NW, et al. Vitrectomy with internal limiting membrane peeling versus no peeling for idiopathic full-thickness macular hole. *Ophthalmology*. 2014;121(3):649–655.
- Bae K, Kang SW, Kim JH, Kim SJ, Kim JM, Yoon JM. Extent of inner limiting membrane peeling and its impact on macular hole surgery outcomes: a randomized trial. *Am J Ophthalmol*. 2016;169:179–188.
- Salter AB, Folgar FA, Weissbrot J, Wald KJ. Macular hole surgery prognostic success rates based on macular hole size. *Ophthalmic Surg Laser Imag*. 2012;43(3):184–189.
- Stec LA, Ross RD, Williams GA, Trese MT, Margherio RR, Cox Jr MS. Vitrectomy for chronic macular holes. *Retina*. 2004;24(3):341–347.
- Charles S, Randolph JC, Neekhra A, Salisbury CD, Littlejohn N, Calzada JI. Arcuate retinotomy for the repair of large macular holes. *Ophthalmic Surg Lasers Imaging Retina*. 2013;44(1):69–72 Jan-Feb.
- Alpatov S, Shchuko A, Malyshev V. A new method of treating macular holes. *Eur J Ophthalmol*. 2007;16:246–251.
- Kapoor KG, Khan AN, Tieu BC, Khurshid GS. Revisiting autologous platelets as an adjuvant in macular hole repair: chronic macular holes without prone positioning. *Ophthalmic Surg Laser Imag*. 2012;43:291–295.
- Chen SN, Yang CM. Lens capsular flap transplantation in the management of refractory macular hole from multiple etiologies. *Retina*. 2016;36(1):163–170.
- Rizzo S, Genovesi-Ebert F, Vento A, Cresti F, Miniaci S, Romagnoli MC. Heavy silicone oil (Densiron-68) for the treatment of persistent macular holes: densiron-68 endotamponade for persistent macular holes. *Graefes Arch Clin Exp Ophthalmol*. 2009;247(11):1471–1476.
- Michalewska Z, Michalewski J, Adelman RA, Nawrocki J. Inverted internal limiting membrane flap technique for large macular holes. *Ophthalmology*. 2010;117:2018–2025.
- Oliver A, Wojcik E. Macular detachment for treatment of persistent macular hole. *Ophthalmic Surg Laser Imag*. 2011;42:516–518.
- Wong R, Howard C, Orobona GD. Retina expansion technique for macular hole apposition report 2: efficacy, closure rate, and risks of a macular detachment technique to close large full-thickness macular holes. *Retina*. 2017 Aug 14 (In press).
- Kusuhara S, Teraoka Escaño MF, Fujii S, et al. Prediction of postoperative visual outcome based on hole configuration by optical coherence tomography in eyes with idiopathic macular holes. *Am J Ophthalmol*. 2004;138:709e16.
- Gupta B, Laidlaw DAH, Williamson TH, et al. Predicting visual success in macular hole surgery. *Br J Ophthalmol*. 2009;93:1488–1491.
- Wong R. Novel surgical technique for closure of large full-thickness macular holes. *Retina*. 2013;33:1977–1979 13.
- Gurelik G, Sul S, Kılıç G, Özsaygılı C. A modified foveal advancement technique in the treatment of persistent large macular holes. *Ophthalmic Surg Lasers Imaging Retina*. 2017;48(10):793–798 Oct 1.
- Guerin CJ, Anderson DH, Fariss RN, Fisher SK. Retinal reattachment of the primate macula. Photoreceptor recovery after short-term detachment. *Invest Ophthalmol Vis Sci*. 1989;30:1708–1725.