



Bilateral macular detachment: Choroid as a sanctuary of acute lymphoblastic leukemia



Agustina Adaniya (MD)^{a,*}, Pablo Bazterrechea (MD)^a, José Ignacio Trucco (MD)^a,
Bernardo Ariel Schlaen (PhD, MD)^a, Gustavo Kusminsky (MD)^a,
Mario Joaquin Saravia (MD, PhD)^b

^a Hospital Universitario Austral, Pilar, Buenos Aires, Argentina

^b Buenos Aires Macula, Buenos Aires, Argentina

ARTICLE INFO

Keywords:

Acute lymphoblastic leukemia
Bilateral macular detachment
Choroid
Sanctuary
Total body irradiation (TBI)
Leukemic relapse

ABSTRACT

Purpose: To describe a bilateral macular detachment as the only sign of acute lymphoblastic leukemia relapse and prompt reversal with total body irradiation without ocular protection.

Observations: We present the case of a 20-year-old patient, diagnosed with a high-risk phy-negative, pre-B acute lymphoblastic leukemia (ALL), with a positive MLL gene rearrangement. After a Berlin-Frankfurt-Munster-like regimen chemotherapy protocol and a first complete remission, ALL relapse was diagnosed, so he was commenced on a FlaG-Ida protocol (fludarabine, idarubicin, granulocyte-colony stimulating factor, and high-dose cytarabine). He achieved a second complete remission with positive minimal residual disease and was scheduled for urgent allogeneic bone marrow transplant.

Five days before the conditioning regimen was initiated, the patient complained of visual loss in the left eye and then in the right eye. Ophthalmological evaluation showed a best corrected visual acuity of the right eye (OD) of 20/100 and of the left eye (OS) of 20/400. Optical coherence tomography (OCT) showed a bilateral serous sub-foveal detachment. The sub-foveal choroidal thickness was measured by enhanced depth imaging (EDI-OCT) and showed a significant increase (OD 836 μm and OS 1036 μm) compared with normal (average 310 μm). This choroidal thickness increase, associated with the serous macular detachment, was interpreted as a choroidal leukemic infiltration.

A lumbar puncture with cytologic studies and flow cytometry was performed, showing no evidence of central nervous system (CNS) involvement of leukemia. CNS and orbital magnetic nuclear resonance imaging showed no pathology. No extramedullary involvement could be confirmed.

Retinal fluorescein angiography showed multiple and diffuse leakage points (pinpoint pattern) within the macular area. This pattern reinforced our presumptive diagnosis, even though the lumbar puncture and flow cytometry were negative.

The hematologist decided to proceed with the bone marrow transplant. A myeloablative conditioning regimen was delivered, based on total body irradiation (TBI) with a total dose of 12 Gy plus fludarabine 30 mg/m² for five days. No ocular protection was used during TBI.

Only 2 h after TBI commenced, the patient reported a significant improvement in his visual acuity. We confirmed 20/20 in both eyes. The OCT showed a dramatic decrease in the choroidal thickness measurement (OD 387 μm and OS 408 μm compared with 836 μm and 1036 μm measured before radiotherapy).

Conclusions and importance: Complete ophthalmological evaluation and EDI-OCT choroidal thickness measurement could be fundamental tools necessary to determine CNS involvement of ALL, even in cases with negative cerebrospinal fluid and brain imaging.

The central nervous system (CNS) and the testes have been proposed as sanctuaries for leukemic cells.^{1,2} Although the eye is considered a

part of the CNS, it is frequently not included in the initial evaluation of patients with acute leukemia.

* Corresponding author. 2425 Malabia Street, 7th floor, Buenos Aires, 1425, Argentina. Tel.: +54 11 54970391.

E-mail addresses: agustina.adaniya@gmail.com (A. Adaniya), pablozazi@hotmail.com (P. Bazterrechea), ariel.schlaen@gmail.com (B.A. Schlaen), mario.saravia@gmail.com (M.J. Saravia).

<https://doi.org/10.1016/j.ajoc.2020.100746>

Received 9 February 2020; Received in revised form 6 May 2020; Accepted 11 May 2020

Available online 13 May 2020

2451-9936/© 2020 The Authors. Published by Elsevier Inc. This is an open access article under the CC BY-NC-ND license (<http://creativecommons.org/licenses/by-nc-nd/4.0/>).

We present the case of a 20-year-old patient, diagnosed with a high-risk phy-negative, pre-B acute lymphoblastic leukemia (ALL), with a positive MLL rearrangement. The complex karyotype on cytogenetic analysis was 46XY, t(1:19)/46X/Y, -6, +DER(6)t(1;6), 47XY, IDEM+, +DER(19) T(1;19)/46XY. Assessment of CNS involvement yielded a negative cerebrospinal fluid flow cytometry (FC) and normal CNS computed tomography. He was initially treated with a Berlin-Frankfurt-Munster-like chemotherapy protocol, achieving a first complete remission with negative minimal residual disease. An allogeneic bone marrow transplant was scheduled. Prior to the initiation of the procedure, he presented with high fever, high leukocyte count, and a peripheral blood smear that showed 25% lymphoblasts. ALL relapse was diagnosed and he was commenced on a FlaG-Ida protocol (fludarabine, idarubicin, granulocyte-colony stimulating factor, and high-dose cytarabine). He achieved a second complete remission with positive minimal residual disease. He was scheduled again for an urgent allogeneic bone marrow transplant.

Five days before the initiation of the conditioning regimen, the patient complained of visual loss in his left eye. The ophthalmological evaluation showed a best corrected visual acuity (BCVA) of the right eye (OD) of 20/20 and of the left eye (OS) of 20/100. Optical coherence tomography (OCT) showed a serous sub-foveal detachment in the OS.

Two days later, the OD was also affected. The BCVA was 20/100 and 20/400 in the OD and OS, respectively, and OCT revealed a bilateral macular detachment. The sub-foveal choroidal thickness was measured by enhanced depth imaging (EDI-OCT), showing a significant increase (OD 836 μm and OS 1036 μm) compared with normal (average 310 μm). The increased thickness, associated with the serous macular detachment, was interpreted as a choroidal leukemic infiltration (Fig. 1a and b).

Two lumbar punctures with cytologic studies, FC, and opening pressure measurements were performed. No evidence of CNS involvement of leukemia was found. CNS and orbital magnetic resonance imaging showed no pathologic images, only slight peripheral optic nerve enhancement of contrast. Optic neuritis was ruled out by OCT

nerve fiber imaging.

Retinal fluorescein angiography showed multiple and diffuse leakage points (pinpoint pattern) within the macular area. This pattern reinforced our presumptive diagnosis, even though the lumbar puncture and FC were negative (Fig. 1c and d). Due to the morbidity associated with the procedure, a choroidal biopsy was ruled out.

The hematologist decided to proceed with the bone marrow transplant. A myeloablative conditioning regimen was delivered, based on total body irradiation (TBI) with a total dose of 12 Gy plus fludarabine 30 mg/m² for five days. No ocular protection was used during TBI.

Two hours after TBI commenced, the patient experienced retro-ocular bilateral transient pain, followed by significant improvement in his visual acuity. Two days after the procedure, the BCVA was 20/20 in both eyes. The OCT showed a dramatic bilateral choroidal thickness decrease (OD 387 μm and OS 408 μm compared with 836 μm and 1036 μm measured before radiotherapy; Fig. 2a,b,c,d). We ruled out other causes of retro-ocular pain.

1. Discussion

Because the CNS and the testes are considered sanctuary sites for leukemic cells, every patient with an ALL diagnosis should undergo CNS examination to determine initial involvement as part of staging. A cerebrospinal fluid assessment is essential and imaging (usually magnetic resonance imaging) can be performed.³ Although the eye is considered part of the CNS, ophthalmologic evaluation is not always included in the initial screening for extramedullary compromise. In our patient, although he had achieved complete remission with chemotherapy, the choroid was interpreted as a sanctuary site for blasts, being an ideal tissue for survival due to the high blood flow rate, with oxygen availability.

The decrease in visual acuity was the main subjective clinical manifestation, and the serous macular detachment associated with choroidal enlargement measured by OCT was the principal objective

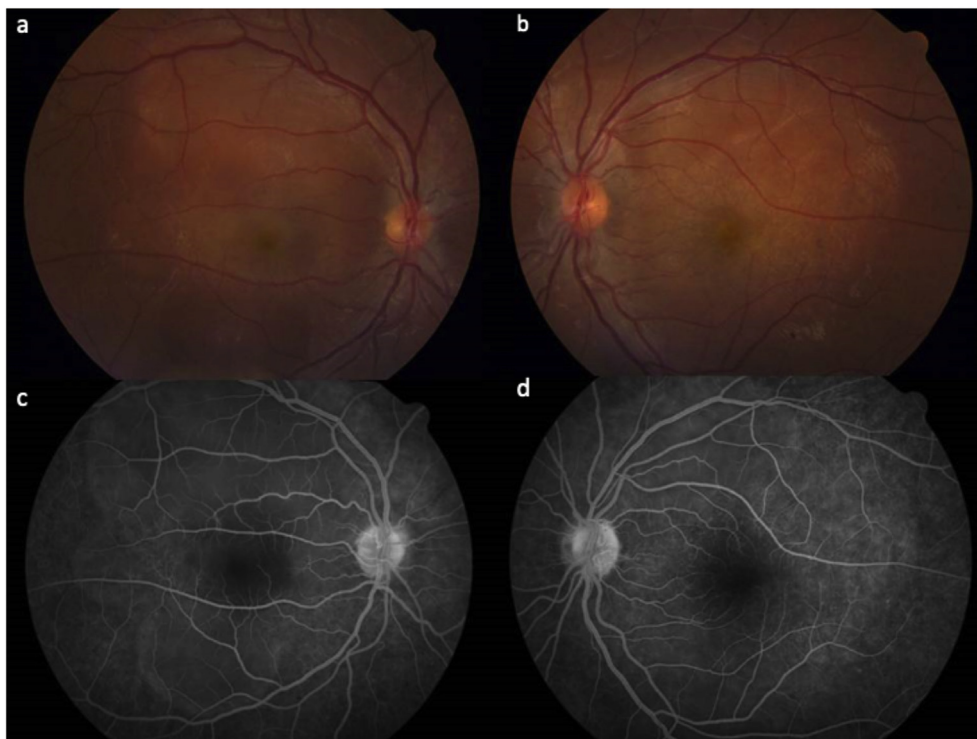


Fig. 1. Fundus photography showed macular serous detachment in both eyes (a and b). Retinal fluorescein angiography (arterial-venous phase) revealed multiple and diffuse leakage points (pin point pattern) within the macular area (c and d).

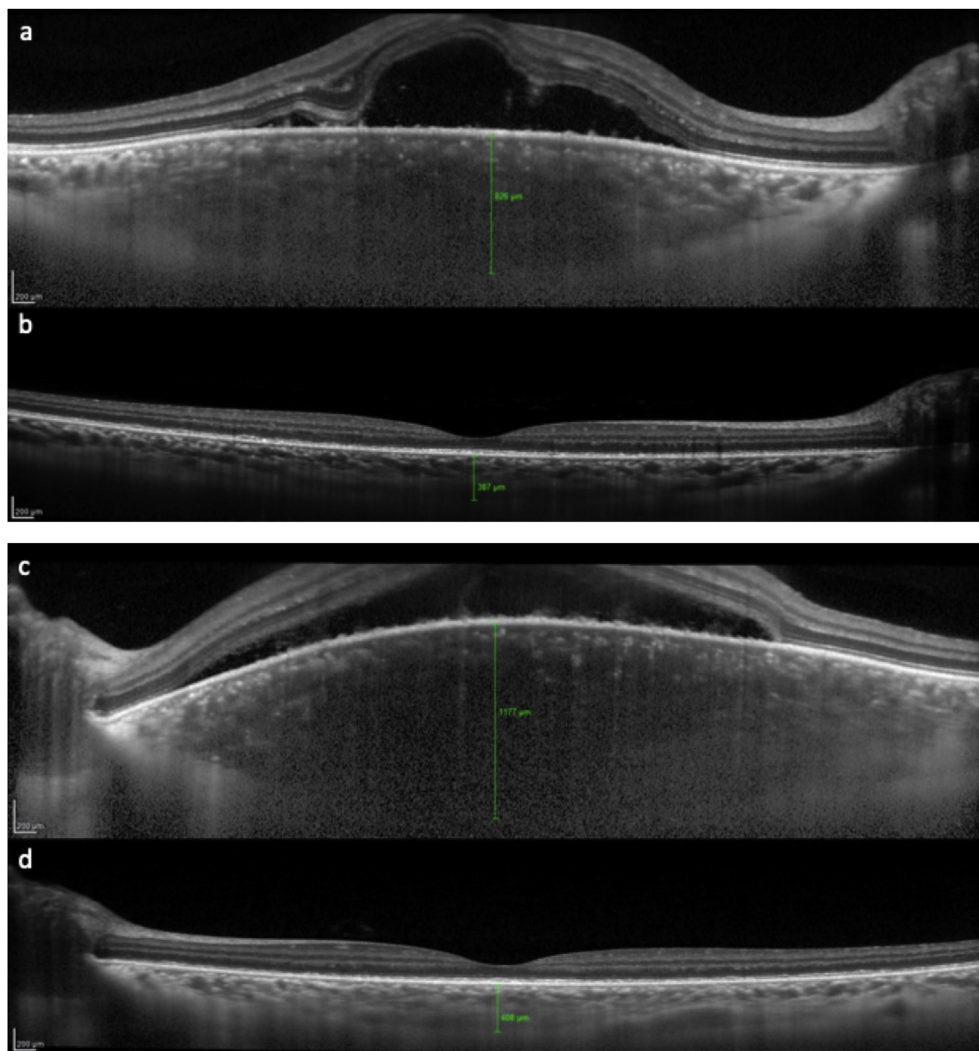


Fig. 2. Optical Coherence Tomography (OCT) images comparing the sub-foveal choroidal thickness measured by EDI (Enhanced Depth Imaging) in both eyes before and after treatment. There was a significant increase in choroidal thickness in OD 836 μm (a) and in OS 1036 μm (c). After TBI was installed, both eyes showed regression to normal width (b and d).

sign.

One hundred and thirty-five eyes obtained from autopsies of patients who died of leukemia were included in a case series report, delivering interesting results. It showed both intra- and extravascular choroidal infiltration in 62 (45.9%) of the samples.⁴ Even though this was a postmortem case series, and we assume the patients had advanced disease, we consider the choroid a tissue especially susceptible to infiltration. This may be explained by the fact that the choroid is the structure with the highest blood flow by area in the human body, handling 90% of the blood from the ophthalmic artery.⁵

Choroidal infiltration by blasts occurs at the choriocapillaris level, which causes retinal pigment epithelial ischemic damage. Consequently, a disruption in the outer blood-retinal barrier occurs, leading to macular serous detachment.⁶

Our first diagnosis was central serous choroidopathy (CSC). This is a retinal disease that occurs in young males, under stressful conditions or secondary to steroid therapy. The clinical manifestations include unilateral decrease in visual acuity and central serous detachment. Our patient presented with similar clinical characteristics. Differential diagnosis includes choroidal neovascularization, other types of maculopathy, Vogt-Koyanagi-Harada syndrome, papilledema, macular hole, posterior scleritis, vitreous traction, optic pit, hypertensive choroidopathy, lupus choroidopathy, optic neuritis, adverse effects of

medications (especially steroids), and choroidal tumors.⁷

Two days later, as the patient presented a similar involvement of the contralateral eye, this diagnostic suspicion was weakened: bilateral synchronous CSCs are uncommon and occur in elderly patients.⁸ Steroid therapy was withdrawn four weeks before the ocular disease presentation, which made a CSC unlikely. The OCT was repeated and showed a significant choroidal thickening. We hypothesized that choroidal infiltration by leukemic blasts could explain this finding. A previous case report, presenting a leukemic debut, described a choroidal thickening at the OCT.⁹ However, other authors have also reported choroidal attenuation in pediatric patients with leukemia.¹⁰ The fluorescein angiography findings supported our diagnostic presumption, since this pattern has also been observed in previous reports of choroidal infiltration (Fig. 1c and d).^{11,12}

A leukemic relapse was finally assumed. TBI was commenced twice daily for four consecutive days. Two days after TBI, the patient noted a dramatic improvement of his vision in both eyes. We confirmed a BCVA of 20/20 in both eyes.

Enhanced depth imaging (EDI-OCT) confirmed a reversal in the macular detachment and a dramatic reduction of the choroidal thickness, achieving almost normal values. This suggests that irradiation was the main factor that enabled the rapid improvement of visual acuity and reversal of the retinochoroidal changes.

We believe that TBI potentially led to a rapid disappearance of intra- and extravascular blasts, improving choriocapillaris circulation and relieving extravascular choroidal infiltration, with a subsequent decrease of the choroidal vascular stasis. These phenomena probably caused a rapid normalization of the choroidal thickness and absorption of the subretinal fluid. In contrast to our case, Bajenova et al. treated a patient with similar findings with chemotherapy; the detachment disappeared but over a longer period (four weeks), while the choroidal thickness decreased by only a third of its pretreatment measurement.⁹

Further experimental studies are needed to determine dose and radiation regimes in order to revert clinical conditions with minimal adverse effects. TBI without eye protection in these cases may be useful to promptly improve visual acuity. Our findings suggest that a complete ophthalmological evaluation and EDI-OCT choroidal thickness measurement could be fundamental tools to determine CNS involvement in ALL, even in cases with negative cerebrospinal fluid and imaging, and to assess complete disease remission following treatment.

Declaration of competing interest

No conflict of interest.

References

1. Larson RA. Managing CNS disease in adults with acute lymphoblastic leukemia. *Leuk Lymphoma*. 2018 Jan;59(1):3–13 Epub 2017 May 23.
2. Kulkarni KP, Marwaha RK, Trehan A, Bansal D. Testicular relapse in childhood acute lymphoblastic leukemia: the challenges and lessons. *Indian J Canc*. 2010 Apr-Jun;47(2):134–138. <https://doi.org/10.4103/0019-509X.63002>.
3. Hoelzer D, Bassan R, Dombert H, et al. Acute lymphoblastic leukaemia in adult patients: ESMO Clinical Practice Guidelines for diagnosis, treatment and follow up. *Ann Oncol*. 2016;27(Supplement 5):69–82.
4. Leonardy NJ, Rupani M, Dent G, Klintworth GK. Analysis of 135 autopsy eyes for ocular involvement in leukemia. *Am J Ophthalmol*. 1990;109(4):436–444.
5. Ryan SJ. Retinal and choroidal vasculature: retinal oxygenation (Section 1, Chapter 18). *Retina*. fifth ed. Elsevier; 2013.
6. Fackler TK, Bearely S, Odom T, Fekrat S, Cooney MJ. Acute lymphoblastic leukemia presenting as bilateral serous macular detachments. *Retina*. 2006;26(6):710–712.
7. Daruich A, Matet A, Behar-Cohen F. Central serous chorioretinopathy. *Dev Ophthalmol*. 2017:27–38.
8. Liegl R, Ulbig MW. Central serous chorioretinopathy. *Ophthalmologica*. 2014;232(2):65–76.
9. Bajenova N, Vanderbeek B, Johnson MW. Change in Choroidal Thickness after Chemotherapy in Leukemic Choroidopathy. 2012; 2012:203–205.
10. Yalcinbayir O, Baytan B, Geliskan O, et al. Spectral domain optical coherence tomography findings of patients under treatment for pediatric acute lymphoblastic leukemia. *J AAPOS*. 2017;21(2):131–135.e1.
11. Kincaid MC, Green WR. Ocular and orbital involvement in leukemia. *Surv Ophthalmol*. 1983;27:211–232.
12. Golan S, Goldstein M. Acute lymphocytic leukemia relapsing as bilateral serous retinal detachment: a case report. *Eye*. 2011;25(10):1375–1378.