

# Bronchogenic cyst in an unusual location

Guillermo S Gutiérrez<sup>1</sup> , Franco G Gutiérrez<sup>2</sup>,  
Gustavo A Bastianelli<sup>1</sup> and Guillermo N Vaccarino<sup>1</sup>

Asian Cardiovascular & Thoracic Annals  
2021, Vol. 29(1) 44–46  
© The Author(s) 2020  
Article reuse guidelines:  
sagepub.com/journals-permissions  
DOI: 10.1177/0218492320960271  
journals.sagepub.com/home/aan



## Abstract

Bronchogenic cysts are congenital anomalies of the respiratory tract, which can affect children or adults. In adults, these cysts may be asymptomatic or present with symptoms, most often pain or cough. Intrapericardial cysts are rare and represent 27% of bronchogenic cysts. We present the case of a symptomatic adult with an intrapericardial bronchogenic cyst, who underwent surgical resection of the cyst, which successfully relieved his symptoms.

## Keywords

Adult, bronchogenic cyst, cardiac surgical procedures, diagnosis, differential, magnetic resonance imaging, pericardium

## Introduction

Bronchogenic cysts originate from an abnormal or late budding of the embryonic ventral lung or the tracheo-bronchial tree, which occurs between the 26th and the 40th day of gestation. This abnormal bud will subsequently differentiate into a fluid-filled, blind-ending pouch. The location of a bronchogenic cyst depends on the embryological stage of development in which it is formed.<sup>1</sup> Bronchogenic cysts represent 6% to 15% of primary mediastinal masses, but are seldom found inside the pericardium; such cases comprise 27% of all bronchogenic cysts.<sup>2</sup> In adult patients, the clinical presentation varies, and some are asymptomatic. Cough and thoracic pain are the most frequent symptoms, and are generally caused by compression of neighboring structures.<sup>3</sup>

## Case report

A 40-year-old male athlete, with no cardiovascular risk factors, presented with a history of several episodes of thoracic pain and pericardial effusion, which apparently resolved with antiinflammatory drugs, but without a specific diagnosis. He was admitted to our institution with atypical chest pain and no other positive signs on physical examination; enzymes and an electrocardiogram were normal. An echocardiogram showed an ill-defined image behind the left atrium. To better characterize it, computed tomography angiography was performed, which revealed a circumscribed mediastinal mass measuring 73 × 66 × 62 mm, containing areas of

increased density. The mass displaced and compressed the right pulmonary artery, the left superior pulmonary vein, and the superior vena cava (Figure 1A, 1B). To further characterize the mass, magnetic resonance imaging was performed, which demonstrated a cystic image of similar dimensions, hypointense in T1 and hyperintense in T2, without contrast enhancement, solid components, or restricted diffusion foci; such findings suggested a diagnosis of bronchogenic cyst (Figure 1C). No abnormal findings were detected in laboratory parameters, spirometry, coronary angiography, or neck vessel Doppler. With the diagnosis of a mediastinal cyst, surgical resolution was decided. The surgical approach involved a median sternotomy, and the procedure was performed off-pump, dissecting plane by plane to properly identify the mass. Subsequently, to avoid damaging neighboring structures, the mass was evacuated by puncture, and mucous material was obtained (Figure 2A). The cyst wall was resected completely and the procedure was finalized. Total surgery time was 40 min.

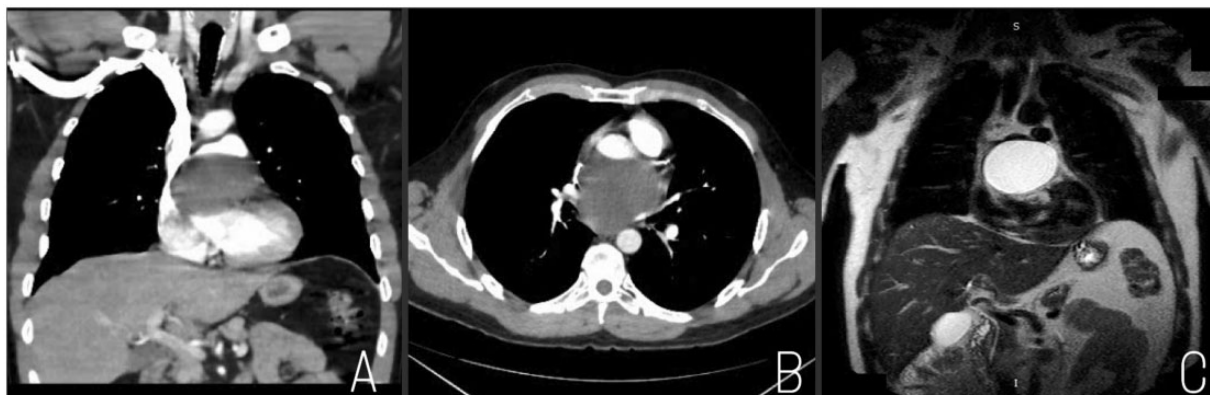<sup>1</sup>Department of Cardiovascular Surgery, Austral University Hospital, Pilar, Buenos Aires, Argentina

<sup>2</sup>Department of Cardiovascular Surgery, Güemes Institute, Resistencia, Chaco, Argentina

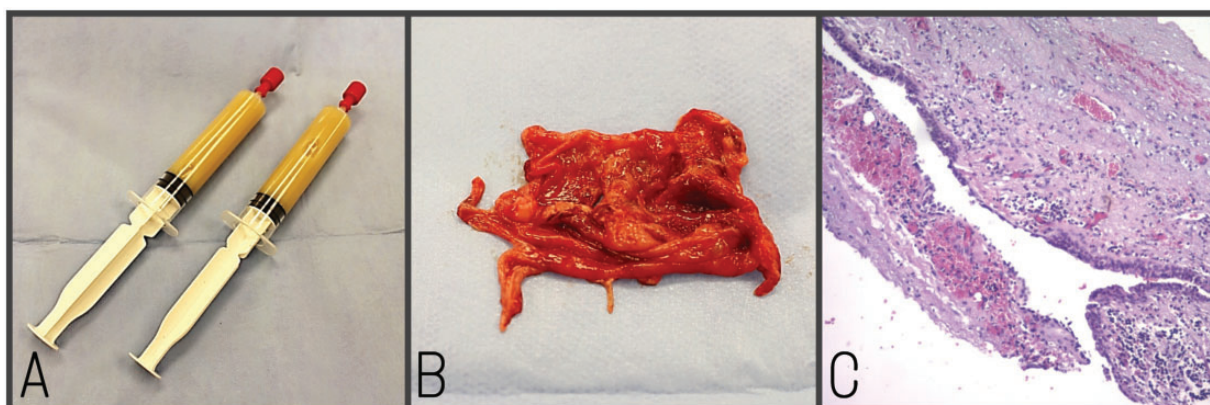
### Corresponding author:

Guillermo S Gutiérrez, Department of Cardiovascular Surgery, Austral University Hospital, 1500# Juan Domingo Peron Av., Buenos Aires 1629, Argentina.

Email: gsgutierrez.cx@gmail.com



**Figure 1.** (A, B) Thoracic computed tomography angiography images. (C) Thoracic magnetic resonance image.



**Figure 2.** Intraoperative images: (A) the fluid contents obtained from the cyst. (B) The specimen obtained from the cyst wall. (C) Microscopy of the cyst wall.

Postoperative recovery was uneventful; the patient did not require inotropic drugs, and was discharged home on the 4th postoperative day with an early return to his usual activities. Pathology revealed morphological features consistent with a bronchogenic cyst (Figure 2B, 2C).

## Discussion

Because of the intrapericardial location in this case, which is extremely rare, diagnostic and therapeutic management differed from that usually described in the literature.<sup>2</sup> Although recurrent pericardial effusion is not a usual presentation of a bronchogenic cyst, imaging methods were essential for decision-making in this patient.<sup>3,4</sup> The cyst's unusual location explains the lack of diagnostic signs on chest radiography, and hence it was necessary to perform computed tomography and/or magnetic resonance imaging to reach a diagnosis.<sup>4</sup> Although both imaging techniques are useful, magnetic resonance imaging provides a better

definition of the cyst and its anatomical relationships, with a low intensity signal in T1 and a high intensity signal in T2.<sup>4</sup>

The treatment of patients with bronchogenic cysts depends on their age and symptoms at the time of diagnosis. An asymptomatic patient may present with clinical manifestations at any time, and also develop life-threatening complications; hence, surgical resection is the best therapeutic strategy when the patient's operative risk allows such an approach.<sup>3</sup> The standard surgical strategy consists of complete excision of the cyst via a thoracotomy or even a thoracoscopic approach. In this case, given the location of the cyst, the approach chosen was a median sternotomy. We considered that this approach provided the best option in case of a potentially catastrophic hemorrhage or if dense adhesions to adjacent structures were encountered, as described by Durieux and colleagues.<sup>5</sup> The prognosis without surgical treatment is increased mortality, but with surgery, the reported complications range from 0% to 14%.<sup>3,4</sup> Pathologic examination of

intraoperative specimens allows differentiation of these cysts from other entities (enteric cysts, neoplasms, cysts of infectious origin) and provides a definitive diagnosis. Resection of bronchogenic cysts in symptomatic patients offers excellent results and avoids serious complications that can occur during the course of this disorder. The approach via a median sternotomy in patients with an intrapericardial cyst is a safe strategy because it allows us to address potential intraoperative complications.

#### **Declaration of conflicting interests**

The author(s) declared no potential conflicts of interest with respect to the research, authorship, and/or publication of this article.

#### **Funding**

The author(s) received no financial support for the research, authorship, and/or publication of this article.

#### **ORCID iD**

Guillermo S Gutiérrez  <https://orcid.org/0000-0003-4532-3279>

#### **References**

1. McAdams HP, Kirejczyk WM, Rosado-de-Christenson ML, Matsumoto S. Bronchogenic cyst: imaging features with clinical and histopathologic correlation. *Radiology* 2000; 217: 441–446.
2. Nair L, Ranawaka Y, Naidoo R. Intrapericardial bronchogenic duplication cyst. *Interact Cardiovasc Thorac Surg* 2014; 19: 311–312.
3. St-Georges R, Deslauriers J, Duranceau A, et al. Clinical spectrum of bronchogenic cysts of the mediastinum and lung in the adult. *Ann Thorac Surg* 1991; 52: 6–13.
4. Suen HC, Mathisen DT, Grillo HC. Surgical management and radiological characteristics of bronchogenic cysts. *Ann Thorac Surg* 2013; 55: 476–481.
5. Durieux R, Lavigne JP, Scagnol I, Defraigne JO. Intrapericardial bronchogenic cyst adherent to the ascending aorta. *Thorac Cardiovasc Surg* 2012; 17: 189–191.